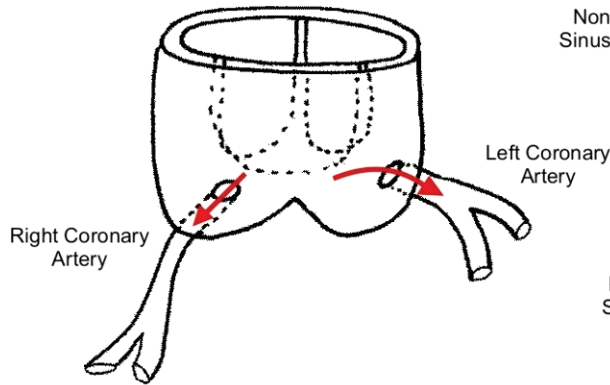
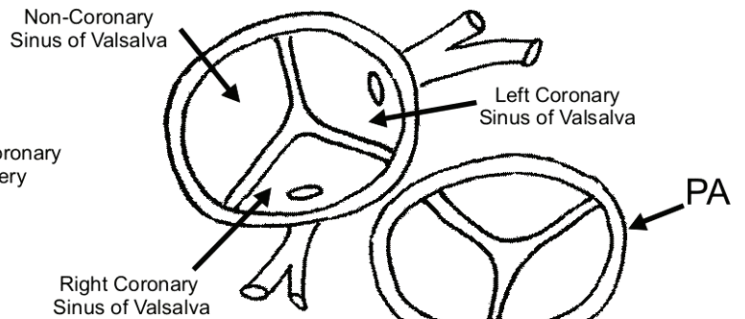


# Anomalous Origin of a Coronary Artery with Intramural Course

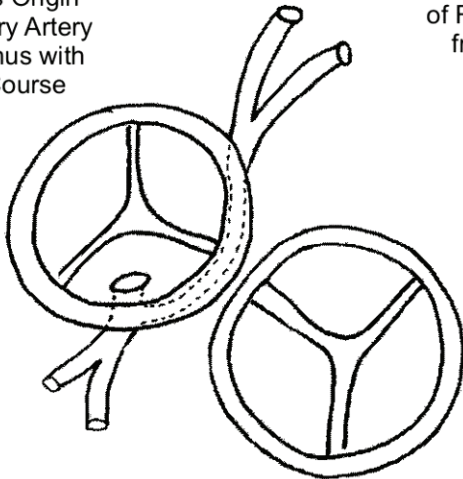
1. Normal Coronary Artery Arrangement



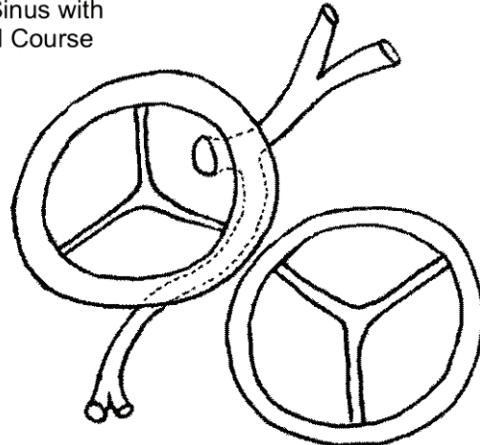
2. Aerial view of Aortic and PA Roots



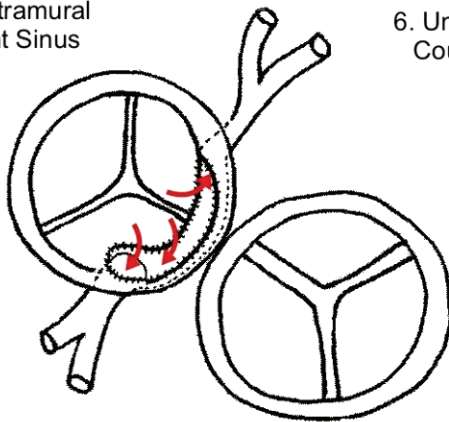
3. Anomalous Origin of Left Coronary Artery from Right Sinus with Intramural Course



4. Anomalous Origin of Right Coronary Artery from Left Sinus with Intramural Course



5. Unroofing of Intramural Course into Right Sinus



6. Unroofing of Intramural Course into Left Sinus

