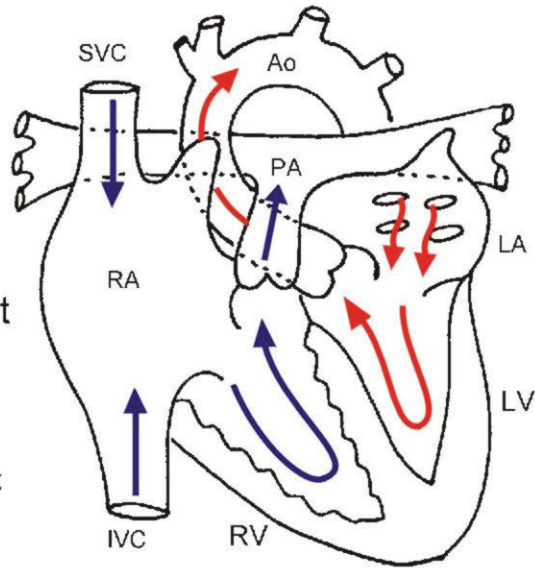
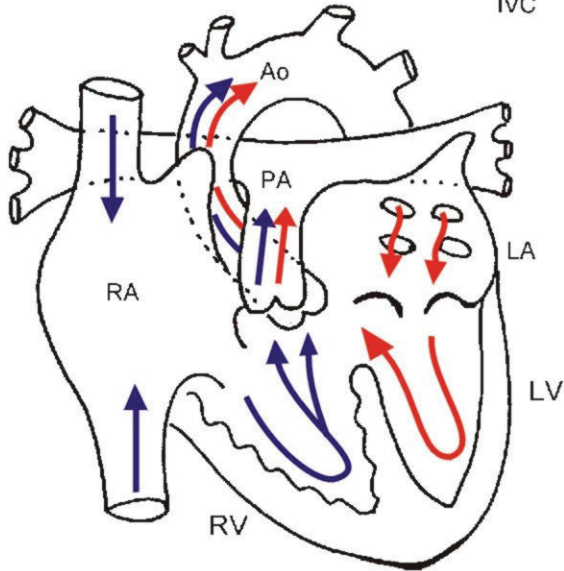


Double Outlet Right Ventricle

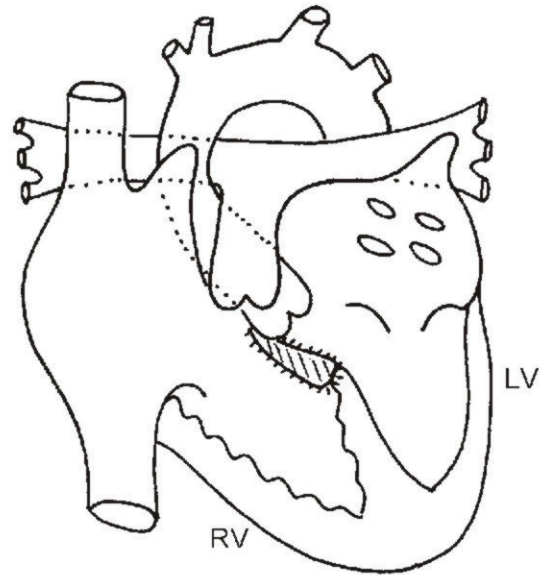
Normal Heart



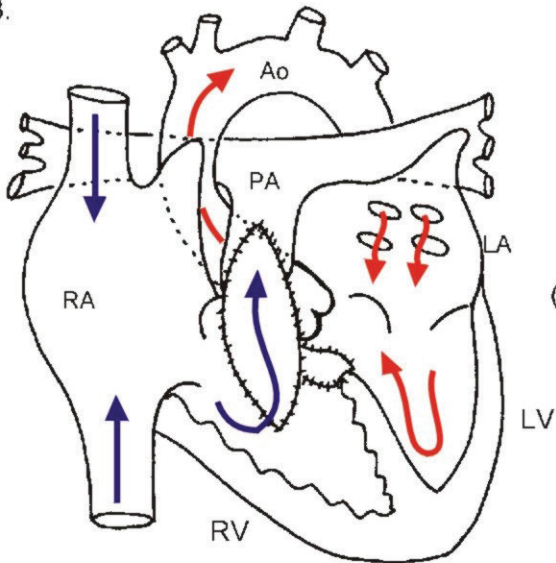
1. Double Outlet Right Ventricle with Ventricular Septal Defect



2.



3.



(OR)

