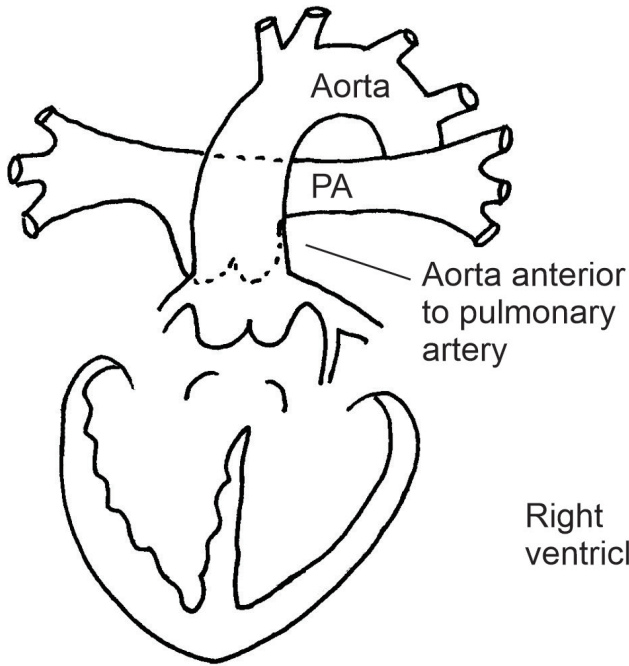
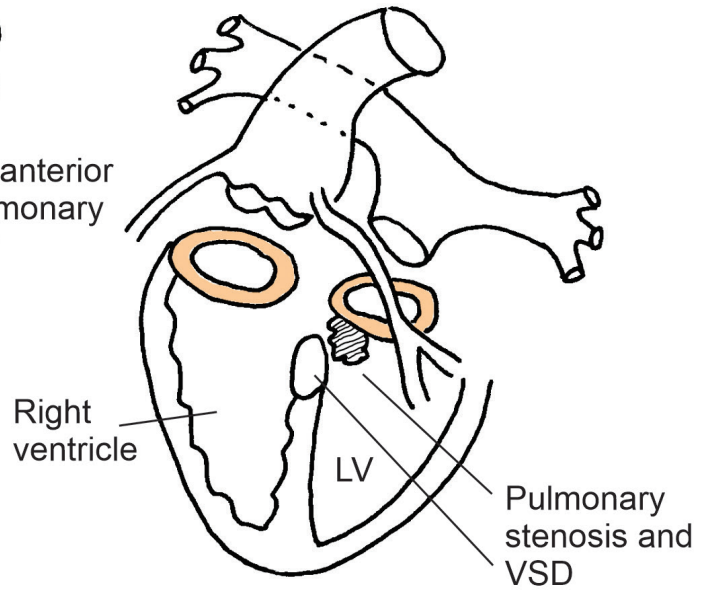


The Nikaidoh Procedure

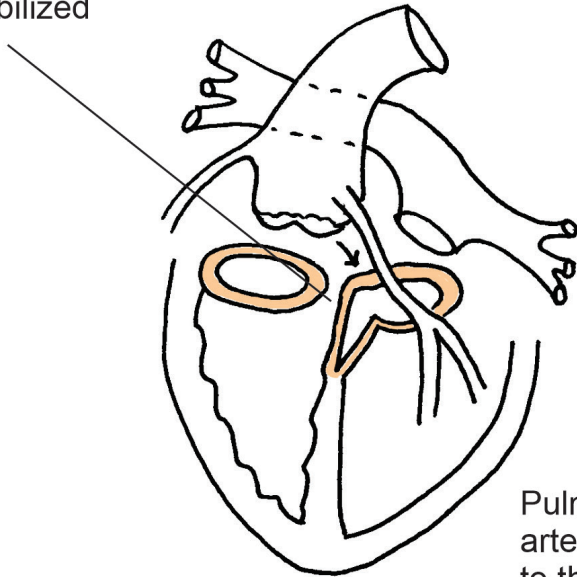
D-Transposition with VSD and pulmonary stenosis (atria not shown)



Great vessels explanted



Left ventricular outflow tract opened widely into the VSD and coronary arteries mobilized



Aortic root shifted posteriorly and implanted with patching of ventricular septum

Pulmonary artery reimplemented to the right ventricle

