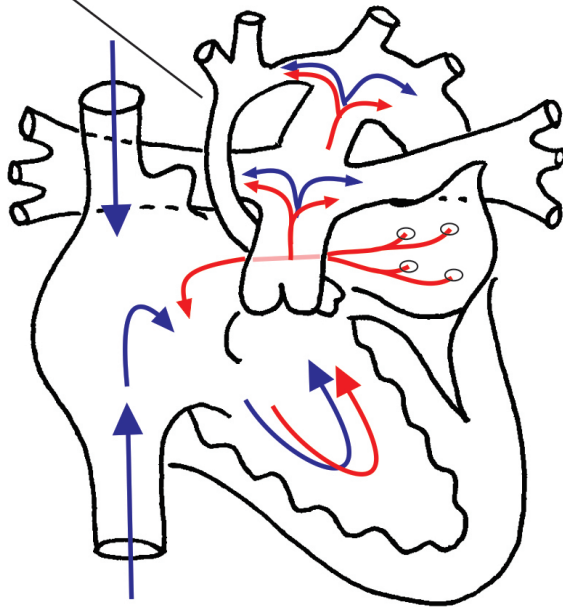


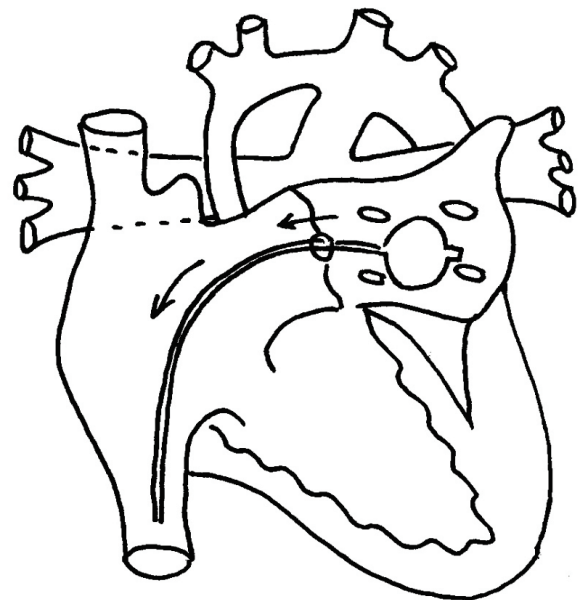
Hybrid Palliation of Hypoplastic Left Heart Syndrome

Hypoplastic ascending aorta

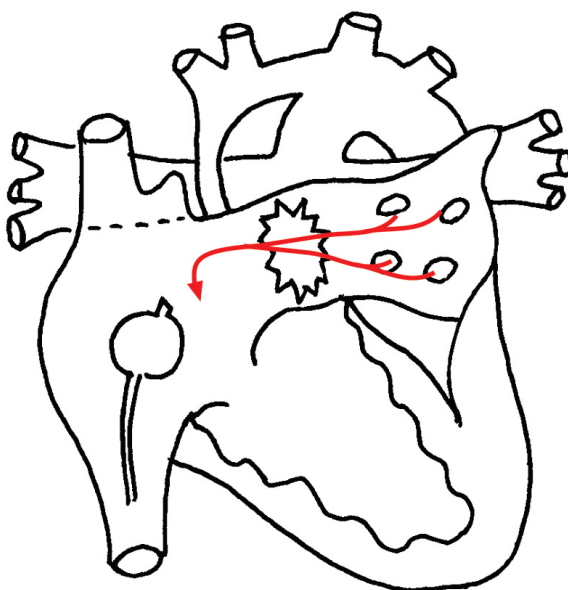
Ductus Arteriosus



Balloon passed across the atrial septum into the left atrium



Atrial septum opened as balloon is pulled back



Stent placed in ductus arteriosus
Pulmonary artery bands placed around left and right branches

