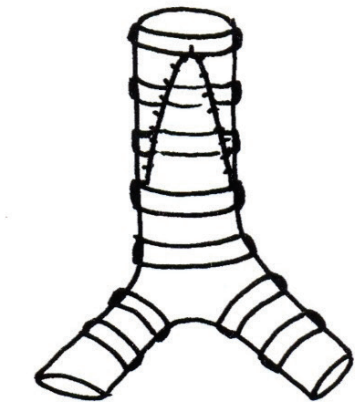
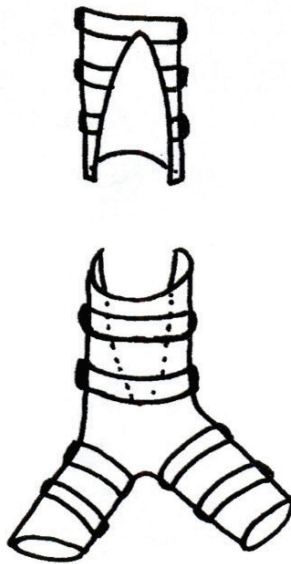
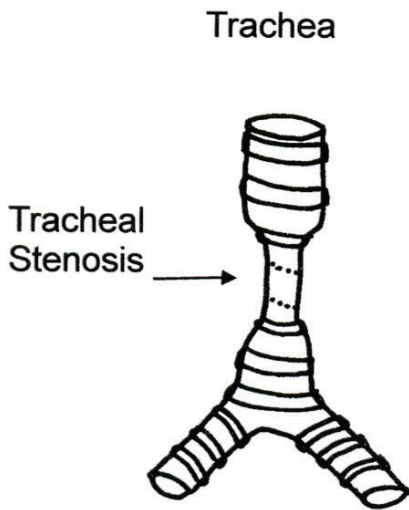
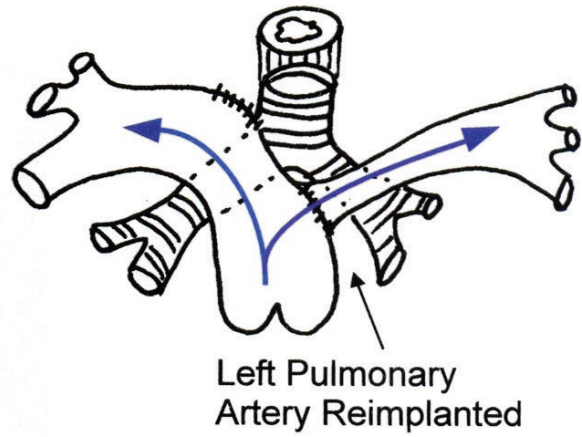
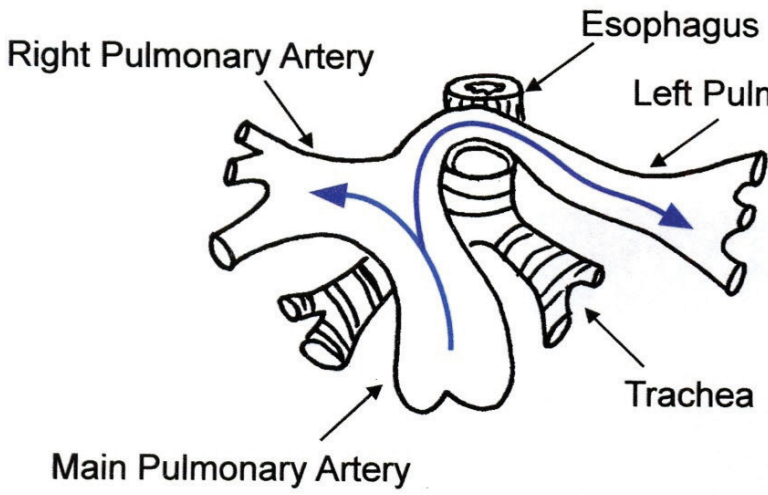


Pulmonary Artery Sling and Tracheal Stenosis



Most severe segment resected
Trachea opened longitudinally

Completed Anastomosis