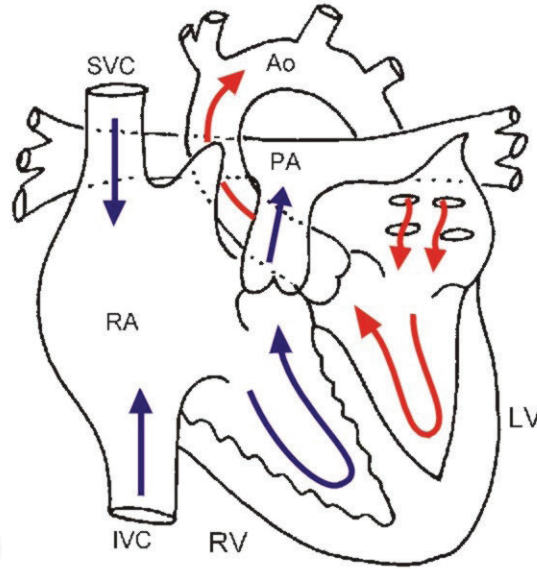
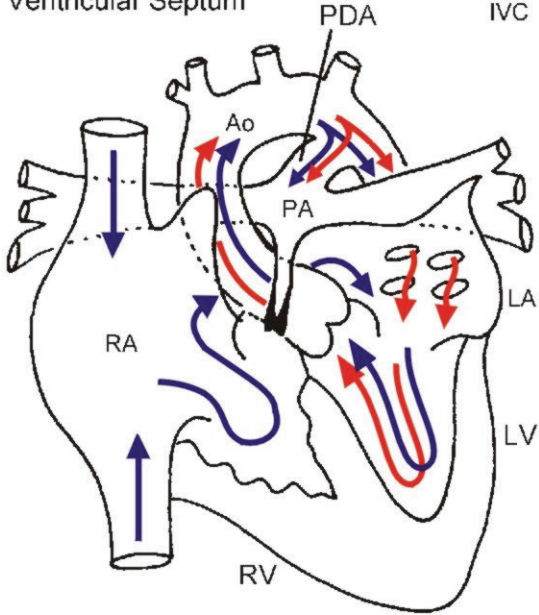


Pulmonary Atresia with Intact Ventricular Septum

Normal Heart



1. Pulmonary Atresia with Intact Ventricular Septum



2.

Blalock-Taussig Shunt

