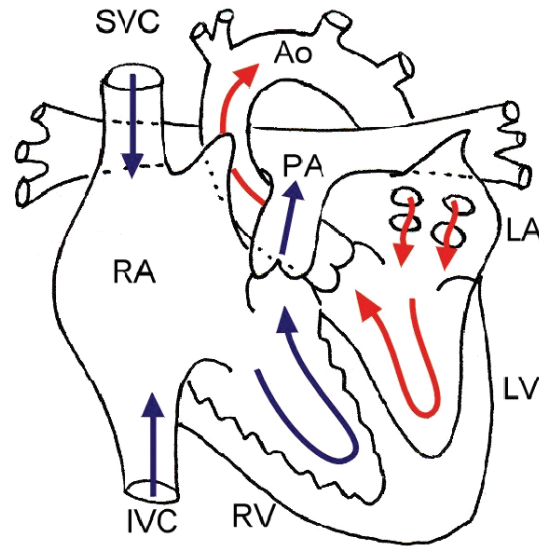


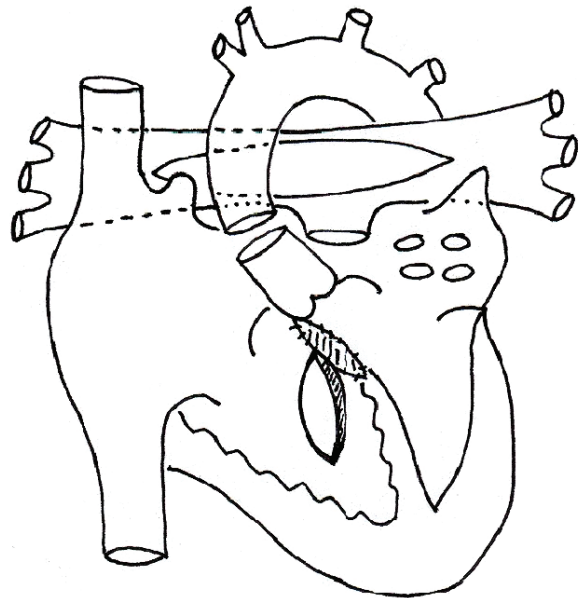
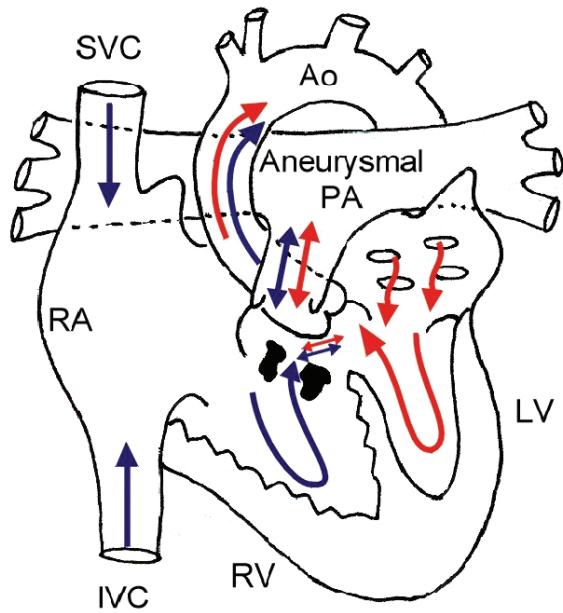
Tetralogy of Fallot with Absent Pulmonary Valve

Normal Heart



1. Tetralogy of Fallot with absent pulmonary valve

2. VSD closed, aorta divided, anterior PA wall resected, RV opened, muscle resected



3. PA closed, Ao connected behind PA

4. RV to PA valved conduit placed

