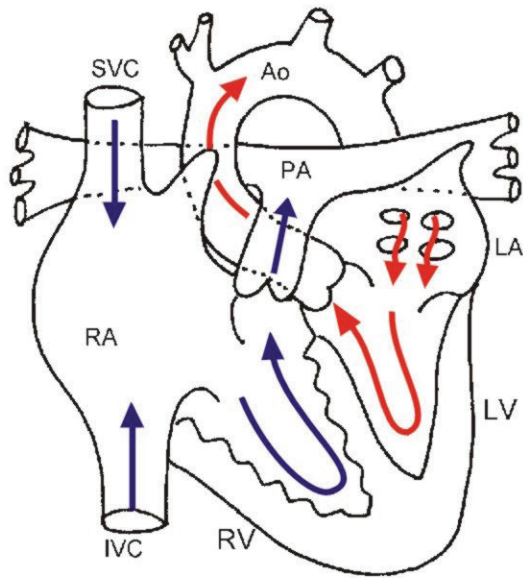
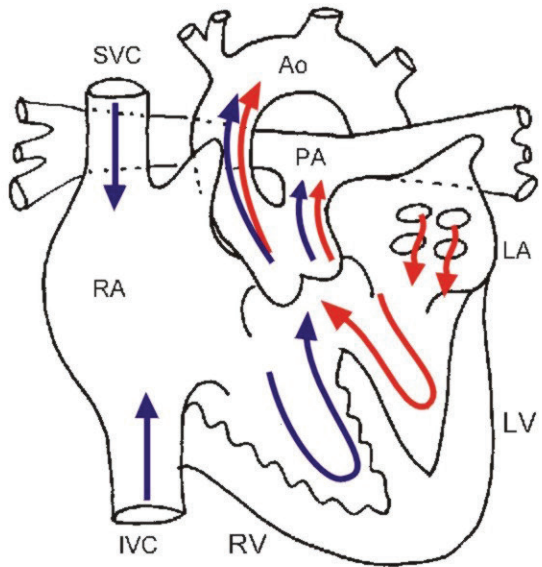


Truncus Arteriosus

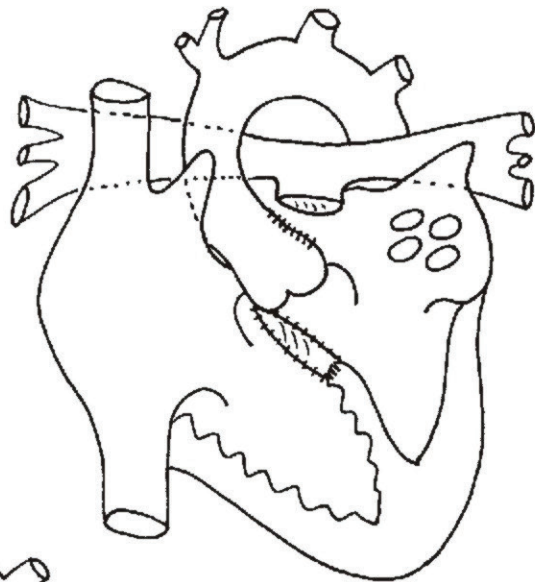
Normal Heart



1. Truncus Arteriosus



2.



3.

