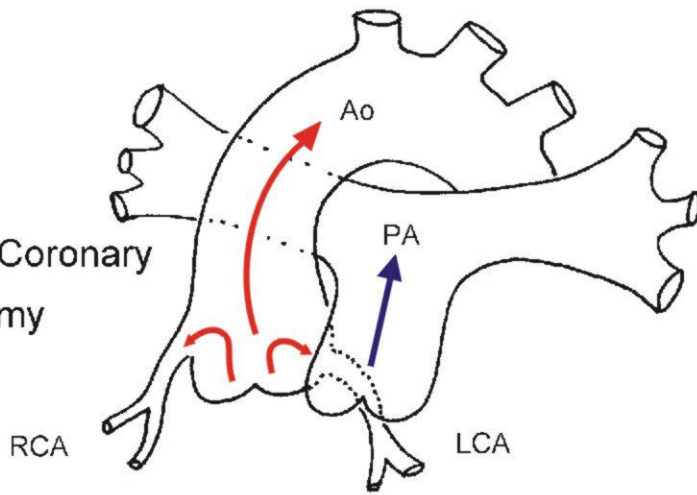
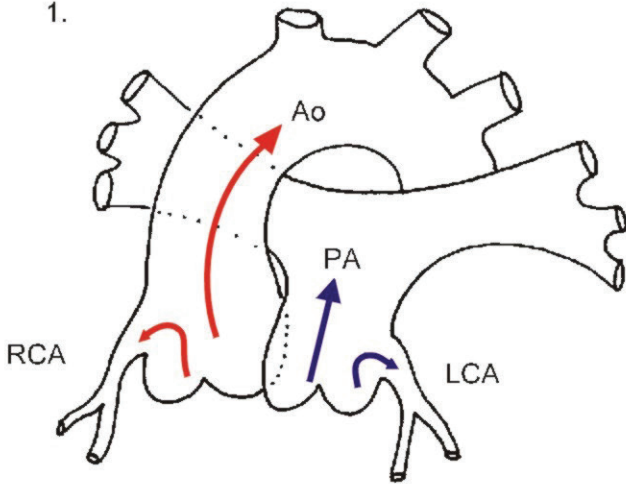


Anomalous Left Coronary Artery

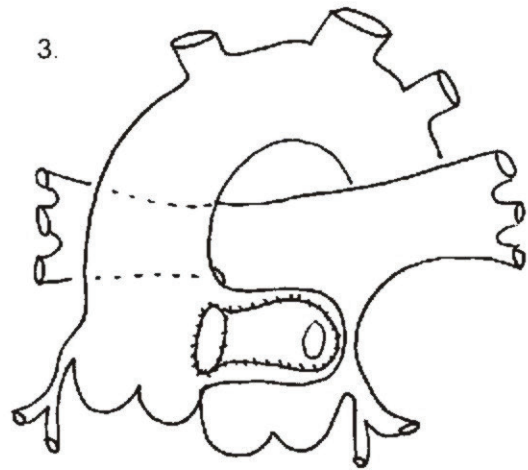
Normal Coronary Anatomy



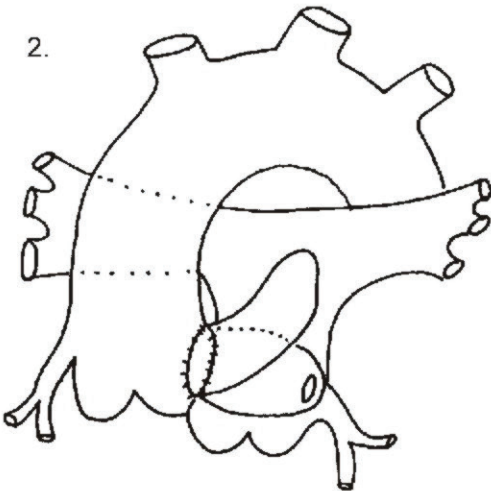
1.



3.



2.



4.

