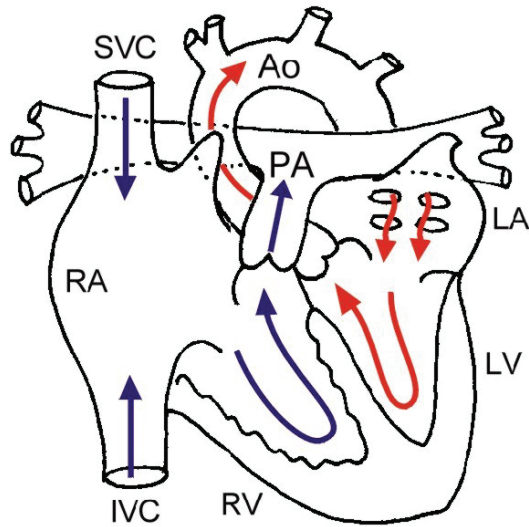


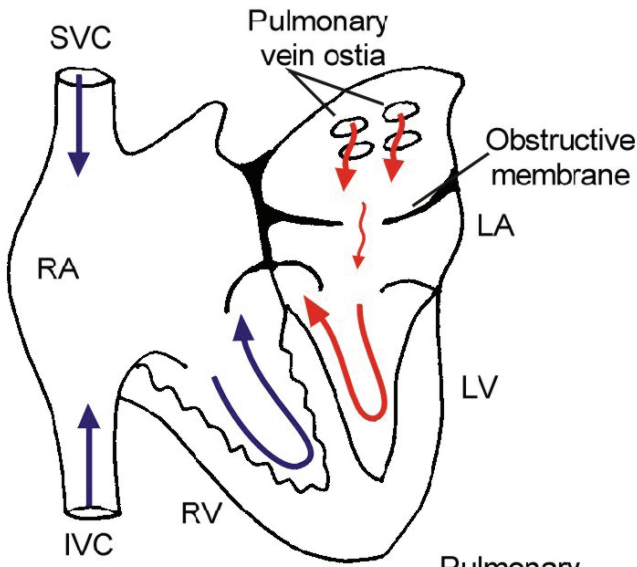
Cor Triatriatum

Normal Heart

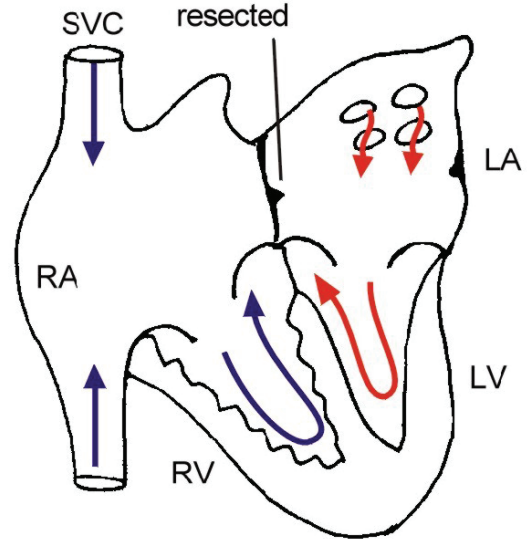


Great Vessels not shown to better illustrate atrial anatomy

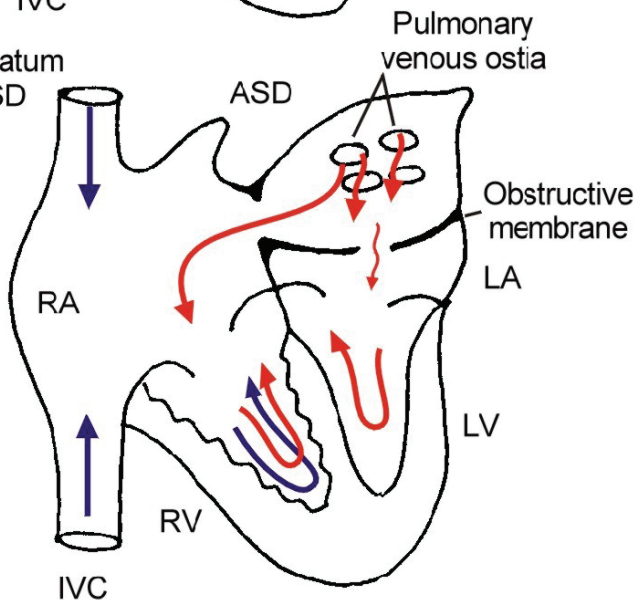
1. Cor Triatriatum with no ASD



2. Obstructive membrane resected



Cor Triatriatum with ASD



ASD patched

