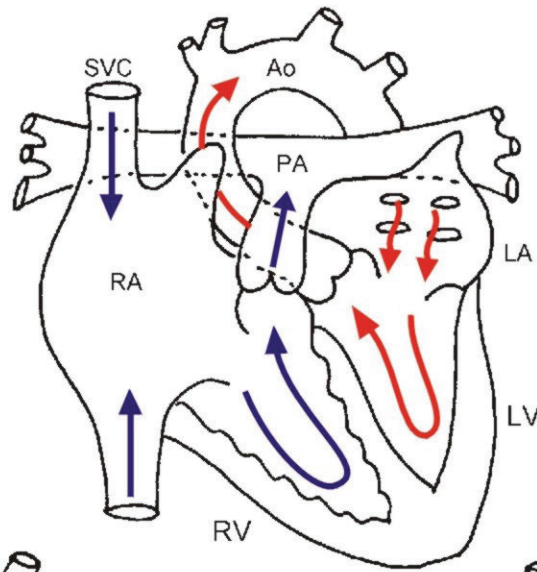
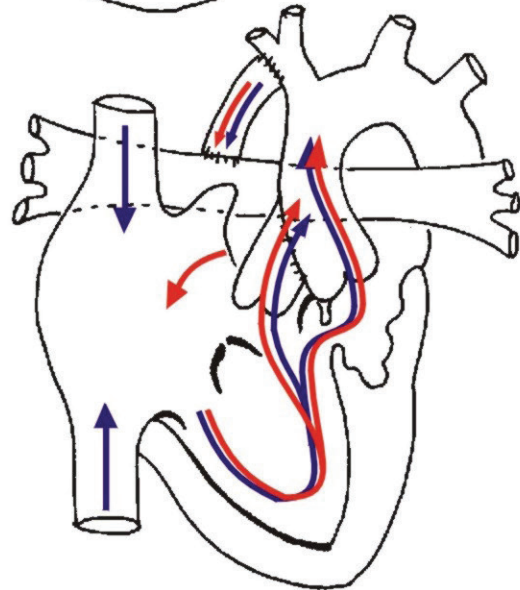
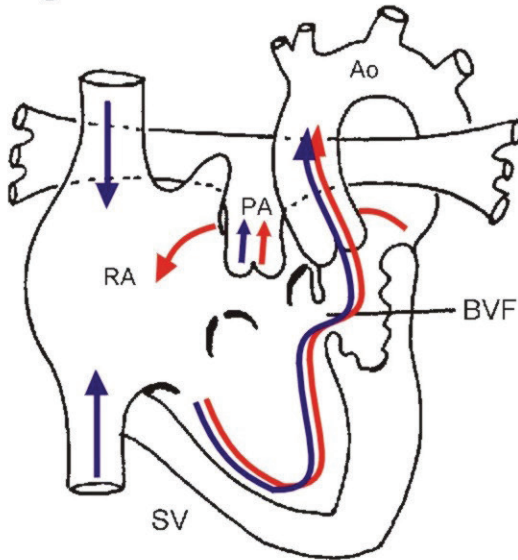


# Damus Kaye Stansel

## Normal Heart



### 1. Damus in Double Inlet Single Left Ventricle



### 2. Damus in Tricuspid Atresia with Transposition

