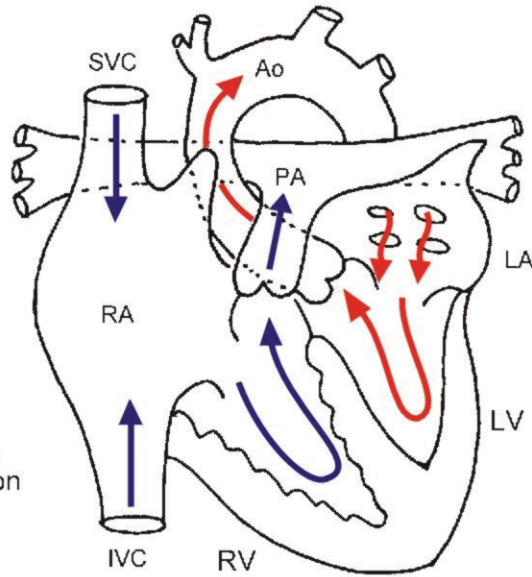
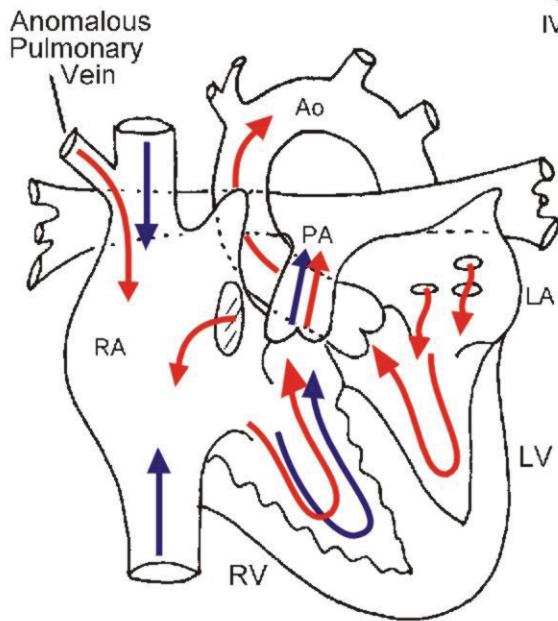


High SVC Partial Anomalous Pulmonary Venous Connection

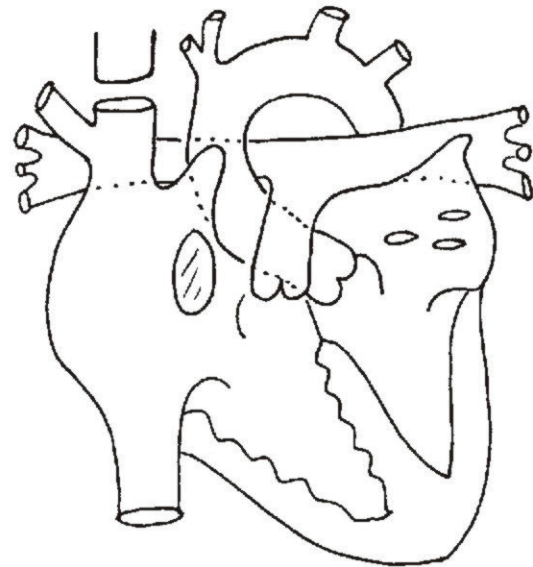
Normal Heart



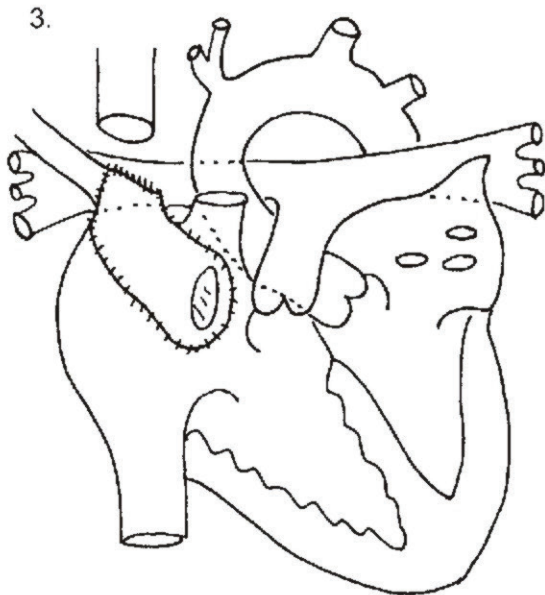
1. High SVC Partial Anomalous Pulmonary Venous Connection



2.



3.



4.

