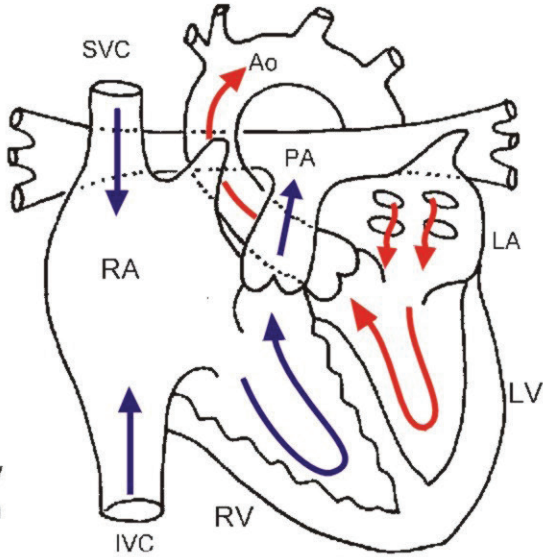


# Primum Atrial Septal Defect

Normal Heart

Normal A-V Valve anatomy  
Great Vessels not shown



Primum Atrial Septal defect  
Great Vessels not shown

