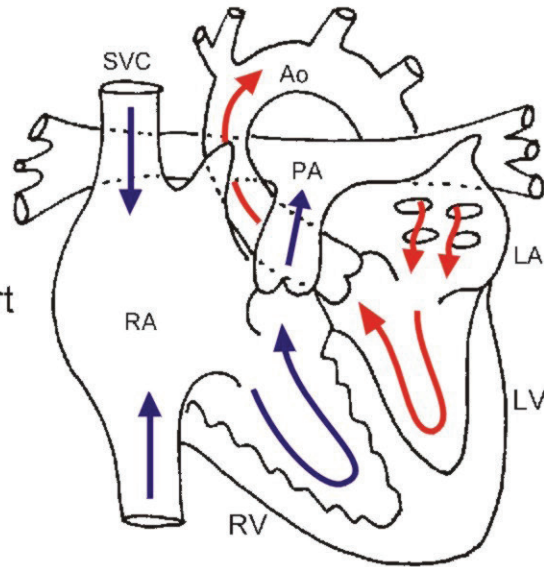
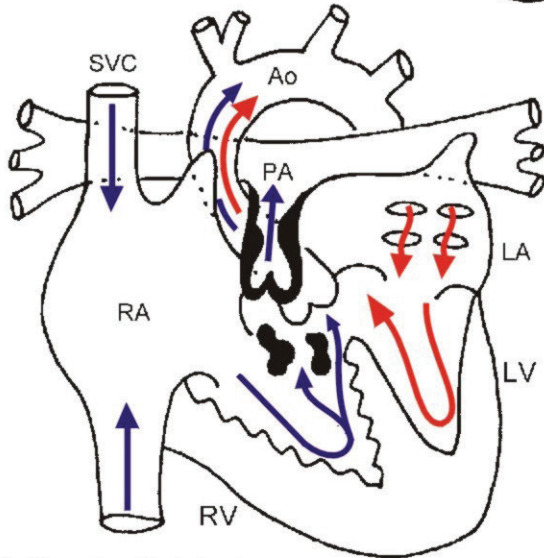


Tetralogy of Fallot

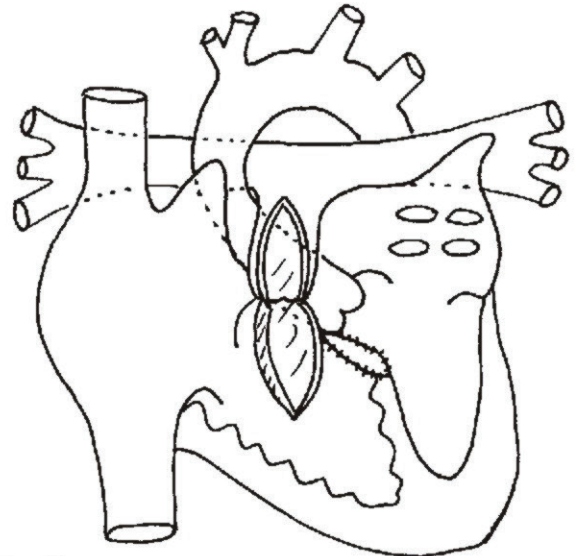
Normal Heart



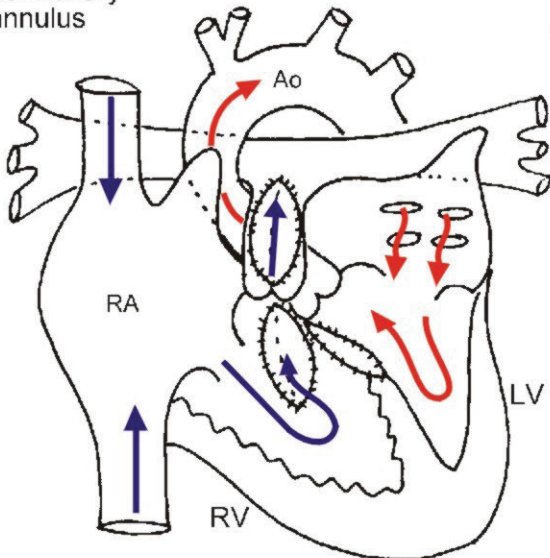
1. Tetralogy of Fallot



2.



3. Repair with intact pulmonary annulus



4. Repair with transannular patch

