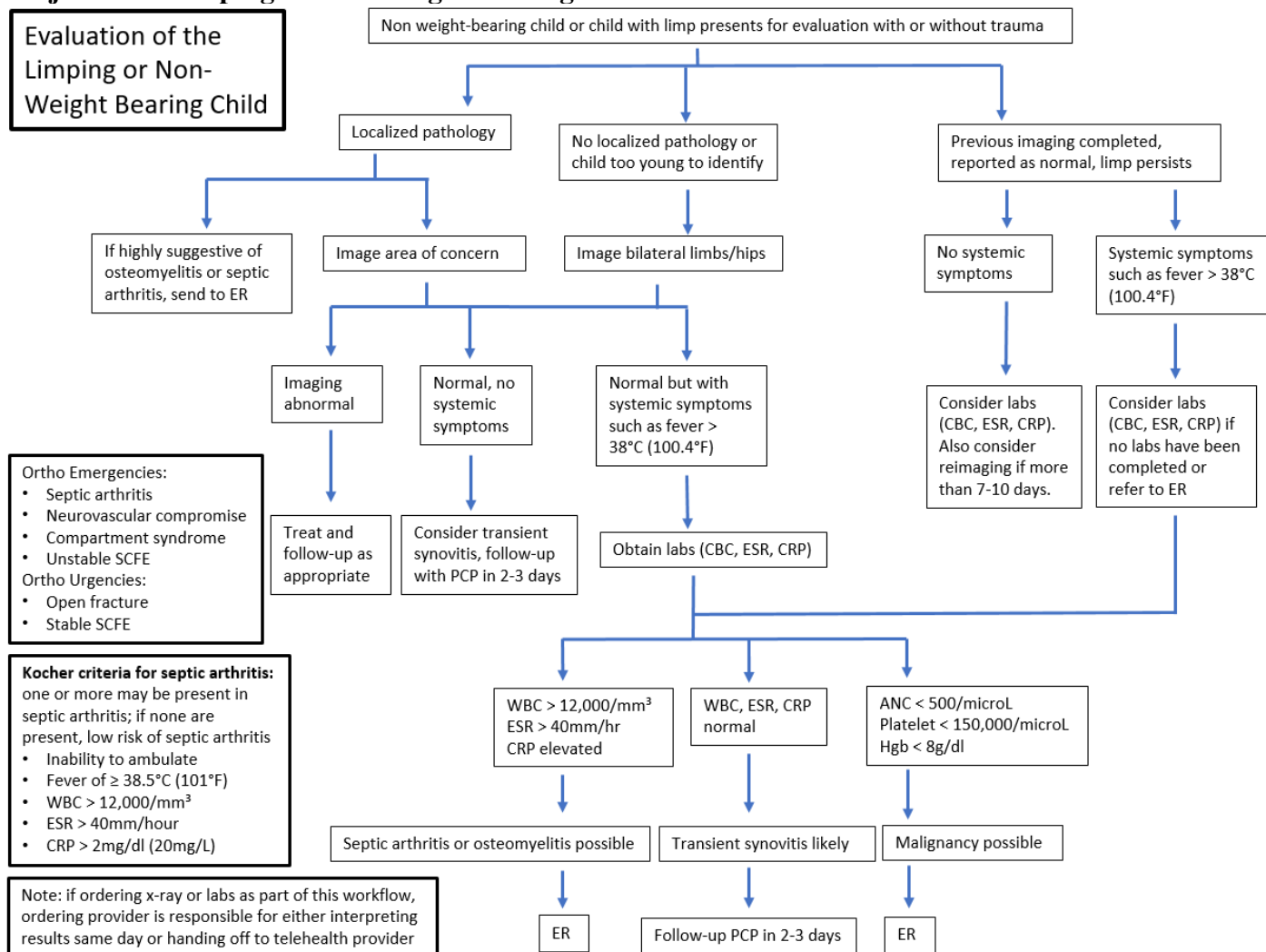


Children's Hospital and Health System, Inc.
Evidence Based Guideline
Children's Urgent Care

Subject: The Limping or Non-Weight Bearing Child



- Ortho Emergencies:**
- Septic arthritis
 - Neurovascular compromise
 - Compartment syndrome
 - Unstable SCFE
- Ortho Urgencies:**
- Open fracture
 - Stable SCFE

- Kocher criteria for septic arthritis:**
 one or more may be present in septic arthritis; if none are present, low risk of septic arthritis
- Inability to ambulate
 - Fever of $\geq 38.5^{\circ}\text{C}$ (101°F)
 - $\text{WBC} > 12,000/\text{mm}^3$
 - $\text{ESR} > 40\text{mm}/\text{hour}$
 - $\text{CRP} > 2\text{mg}/\text{dl}$ ($20\text{mg}/\text{L}$)

Note: if ordering x-ray or labs as part of this workflow, ordering provider is responsible for either interpreting results same day or handing off to telehealth provider

Supersedes: 6/2019

Approved UC Clinical Practice Council and Medical Director 9/2022

Next review 9/2025

UC EVIDENCE BASED GUIDELINE: LIMPING CHILD

Purpose: To evaluate and initiate treatment of the limping or non-weight bearing child.

Definition: Limping is a common pediatric presenting complaint, with an estimated 5% of pediatric emergency room visits due to this chief complaint. Limping is defined as a deviation from normal gait pattern and may be secondary to pain, weakness, or musculoskeletal deformity.

Normal gait is composed of symmetric, rhythmic, and alternating movements made up of the stance and swing phases for each foot. *Stance phase* occurs when the foot is in contact with the ground, while *swing phase* occurs when the foot is in the air.

- Normal gait pattern in children
 - Toddlers have wide-based, short asymmetric steps, foot slapping the floor as they pick up speed, no reciprocal arm rotation with leg, and they fall frequently.
 - 3-5 years: symmetric strides with reciprocal arm rotation.
 - 7 years: adult walk

Etiology and Differential Diagnoses (See Appendix: Etiology and Differential Diagnosis of the Limping Child)

Etiologies range from common to rare and vary by age. Etiologies can be classified as one of the following processes: osseous, articular, neurological, soft tissue, intra-abdominal, or other.

Etiologies could also be classified as: trauma, infectious, immune-mediated, acquired, developmental, neoplastic, referred, benign, musculoskeletal, neurologic, or metabolic.

Narrow the differential diagnosis by classifying the limp according to: gait pattern, presence or absence of pain, age of the child, and anatomic region involved.

The hip is a common source of the pathology.

- Transient synovitis of the hip is a common cause of a limp in children younger than 5 years.
- The overweight limping adolescent with knee, thigh, groin, or hip pain has a slipped capital femoral epiphysis until proven otherwise.
- In general, growing pains usually *do not* cause limping.

In addition to pathology in the lower extremity, limp can also be caused by abnormalities of the nervous system, back, abdomen, or genitourinary tract. The location of pain does not always reflect the location of pathology:

- Hip conditions can cause knee or thigh pain
- Abdominal conditions may cause hip or thigh pain
- Back conditions may have referred pain down the back of the leg or to the lateral thigh

Guideline

Supersedes: 6/2019

Approved UC Clinical Practice Council and Medical Director 9/2022

Next review 9/2025

UC EVIDENCE BASED GUIDELINE: LIMPING CHILD

Subjective Data/History

Obtain history from both patient and parent.

- Age – several conditions are much more likely, depending upon the patient's age
- Pain characteristics
 - Site, focal pain (fracture, infection, malignancy)
 - Onset
 - Acute: trauma, fracture, acute infection
 - Chronic: overuse, apophysitis, SCFE, rheumatic disease, tumor
 - Severity and duration of symptoms
 - Constant pain: malignancy, infection
 - Intermittent pain at rest: malignancy
 - Aggravating and relieving factors
 - Radiation: nerve /spinal cord involvement
 - Quality: achy, dull, burning (nerve involvement), sharp, effect on activity and sleep, timing
 - Weight-bearing: complete or partial refusal, including knee walking
 - Associated abdominal pain: acute abdomen, psoas abscess, neuroblastoma
 - Associated back pain: spinal cord tumor, discitis (or diskitis), vertebral osteomyelitis, spondylolisthesis, or herniated disc.
- Other characteristics
 - History of trauma and mechanism of injury
 - Prior injuries, sports participation (stress injuries)
 - Involvement of both limbs (myositis)
 - Preceding illness
 - History of a viral infection preceding transient synovitis or reactive arthritis
 - History of insect bite (Lyme)
 - History of bleeding disorder (Hemarthrosis)
 - History of preceding diarrhea (reactive arthritis)
 - Preceding pharyngitis (acute rheumatic fever)
 - Systemic symptoms – fever, rash, weight loss, malaise, anorexia, night sweats suggest infective or inflammatory causes like osteomyelitis, septic arthritis, malignancy
 - Morning stiffness (gel phenomenon): Juvenile Idiopathic Arthritis
 - Sexually active: gonococcal arthritis, reactive arthritis
 - Incontinence, sciatica, or leg weakness suggests a spinal cord problem or pelvic mass.
 - Medical, surgical, travel, and immunization history, sick contacts, and history of child's development are also important information

Objective Data/Physical examination

A complete physical examination with an overall assessment of the child, including vital signs.

- Assess the normal limb first

Supersedes: 6/2019

Approved UC Clinical Practice Council and Medical Director 9/2022

Next review 9/2025

UC EVIDENCE BASED GUIDELINE: LIMPING CHILD

- Examine in both supine and seated positions.
- Inspection and palpation are best accomplished when the child is sitting comfortably in the parent's lap if age appropriate.
- Examine child barefooted and minimally clothed for symmetry, stance, pattern of gait, walking, and running.
- Identify the type of limp if able to bear weight and localize the site of pathology. When examining the child's gait, the examiner should pay particular attention to the following features:
 - With an antalgic gait, the stance phase is shorter on the affected side.
 - Circumduction (circular movement of the limb during swing phase) suggests an ankle or foot problem.
 - Downward pelvic tilt during the swing phase (Trendelenburg gait) suggests hip pathology (e.g., developmental dysplasia of the hip, SCFE, or idiopathic avascular necrosis of the hip [Legg-Calvé-Perthes disease]).
 - Toe-to-heel sequence (toe-walking gait, as opposed to the normal heel-to-toe pattern) may indicate a neurologic problem, cerebral palsy, or idiopathic heel cord tightness.
 - Lack of full knee extension in the stance phase implies knee pathology or possible limb length discrepancy.
 - Asking the child to run may unmask an abnormality that is caused by weakness.
- Areas of erythema, swelling, deformity, laceration, ecchymosis, abrasions, and warmth should be noted.
- Distal pulses and perfusion should be assessed and documented.
- Palpate the paraspinal muscles, spinous processes, and iliac spines.
- Range of motion and ligamentous stability of hip, knee, ankle, and foot should be observed.
- Evaluate joints adjacent to painful joint for referred pain. For example hip conditions can present with lateral thigh or knee pain.
- Neurovascular assessment including strength, sensation, and reflexes can also be assessed while the child is sitting or supine.
- Consider measuring and comparing lower-extremity lengths for leg length discrepancy.
- Important physical findings: abdominal mass (neuroblastoma, psoas abscess), abdominal tenderness (acute abdomen).

Diagnostic Studies (See Algorithm: Evaluation of the non-weight bearing or limping child)

Imaging can begin with x-ray of area of concern to rule out fractures, infections, neoplasm

- Both anteroposterior (AP) and lateral (L) views should be completed.
 - Always do an AP and frog-leg view when there is concern about the hip except in SCFE when a true lateral view should be obtained because the frog-leg view can worsen the slip.
- Do not order a unilateral hip series because a small SCFE may be missed in the absence of direct comparison with the opposite hip.

Supersedes: 6/2019

Approved UC Clinical Practice Council and Medical Director 9/2022

Next review 9/2025

UC EVIDENCE BASED GUIDELINE: LIMPING CHILD

- In young children or with non-focal examination, x-ray of both legs should be obtained.
- Limitations of X-ray include:
 - Not showing subtle fractures acutely
 - Changes due to infection may take 7-10 days to develop

Other imaging modalities

- Ultrasound, CT, and MRI are outside the scope of CW Urgent Care

Laboratory studies

- Should be directed by the history and physical examination findings
- Laboratory tests usually are not indicated in the afebrile child with normal physical examination, especially if the limp is associated with an isolated injury and has been present for less than 24 hours.
- Laboratory assessment often begins with a complete blood count (CBC) and differential white blood cell (WBC) count, erythrocyte sedimentation rate (ESR) and C-reactive protein (CRP).
 - These laboratory studies should be obtained when an infectious, inflammatory, or neoplastic etiology is suspected.
 - Lyme studies are indicated in Lyme endemic areas because acute Lyme disease can mimic a septic hip.
 - Blood cultures often are obtained when the index of suspicion is high for septic arthritis or osteomyelitis.

Treatment (See Algorithm: Evaluation of the non-weight bearing or limping child)

- Depends on diagnosis
- For pain management in children with multiple fractures or in severe pain, consider IM Toradol (ketorolac) (0.5 mg/kg/dose; max 30 mg/dose)

Follow-up

Afebrile child with no specific cause:

- Bed rest is important for children with transient synovitis
- Pain relief with NSAID or Acetaminophen as needed
- Follow up with PCP within 2-3 days
 - Consider referral to CW Rheumatology for symptoms present > 4 weeks
- Return if febrile or worsening symptoms

Suspected toddlers fracture with normal x-ray

- Splint and outpatient orthopedic follow up since initial x-ray may be normal.

Febrile child without joint effusion, normal radiographic, and normal lab studies

- Follow up as an outpatient if findings are suggestive of myositis or transient synovitis

Supersedes: 6/2019

Approved UC Clinical Practice Council and Medical Director 9/2022

Next review 9/2025

UC EVIDENCE BASED GUIDELINE: LIMPING CHILD

Amy Romashko, MD
Medical Director, CW Urgent Care

This guideline is designed to serve as a reference for clinical practice and does not represent an exclusive course of treatment nor does it serve as a standard of medical care. Providers should apply their professional judgment to the management of individual patient conditions and circumstances. Children's Hospital and Health System (CHHS) does not make any representation with respect to any sort of industry recognized standard of care for the particular subject matter of this clinical guideline. Additionally, CHHS form documents are subject to change, revision, alteration, and/or revocation without notice.

Supersedes: 6/2019

Approved UC Clinical Practice Council and Medical Director 9/2022

Next review 9/2025

References

- American Academy of Pediatrics. (2014). Evaluating the limping child. In J. F. Sarwark & C. R. LaBella (Eds.), *Pediatric orthopaedics and sports injuries* (pp. 111-120). Elk Grove Village, IL: American Academy of Pediatrics.
- Aronson, P., Posner, J., Dooley, S., Coffin, S., Jacobstein, C. & Lavelle, J. (2017). ED pathway for the evaluation/treatment of the child with suspected septic arthritis. Children's Hospital of Philadelphia. Retrieved from <https://www.chop.edu/clinical-pathway/septic-arthritis-suspected-clinical-pathway>
- Barkin, R.M., Barkin, S.Z., & Barkin, A.Z. (2000). The limping child. *Journal of Emergency Medicine*, 18(3), 331-339.
- Brady, M. (1993). The child with a limp. *Journal of Pediatric Health Care*, 7(5), 226-228.
- Clark, C.M., Fleisher, G.R., Drutz J.E., & Phillips, W.A. (2021). Evaluation of the child with a limp. UpToDate. Retrieved from <http://www.UpToDate.com>
- Clark, C.M., Fleisher, G.R., & Drutz, J.E. (2021). Overview of the causes of limp in children. UpToDate. Retrieved from <http://www.UpToDate.com>
- Herman, M.J. & Martinek, M. (2015). The limping child. *Pediatrics in Review*, 36, 184.
- Kocher, M.S., Mandiga, R., Zurakowski, D., Barnewolt, C., & Kasser, J. (2004). Validation of a clinical prediction rule for the differentiation between septic arthritis and transient synovitis of the hip in children. *Journal of Bone and Joint Surgery*, 86-A(8), 1629-1635.
- Lawrence, L.L. (1988). The limping child. *Emergency Medicine Clinics of North America*, 16(4), 911-929.
- Leung A.K. & Lemay J.F. (2004). The limping child. *Journal of Pediatric Health Care*, 18(5), 219-223.

Supersedes: 6/2019

Approved UC Clinical Practice Council and Medical Director 9/2022

Next review 9/2025

UC EVIDENCE BASED GUIDELINE: LIMPING CHILD

Payares-Lizano, M. (2020). The Limping Child. *Pediatric Clinics of North America*, 67(1), 119-138.

Shah, A.P., Indra, S., Kannikeshwaran, N., Hartwig, E., & Kamat, D. (2015). Diagnostic approach to limp in children. *Pediatric Annals*, 44(12), 552-554, 556.

Treatment information also provided by Allison Duey-Holtz, MSN, CPNP-PC, Children's Wisconsin, Department of Pediatric Orthopedics (personal communication, September 2022).

Supersedes: 6/2019

Approved UC Clinical Practice Council and Medical Director 9/2022

Next review 9/2025

UC EVIDENCE BASED GUIDELINE: LIMPING CHILD

Appendix: Etiology and Differential Diagnosis of the Limping or Non-Weight Bearing Child

	All Ages	Preschool (1-5 years)	School-age (5-12 years)	Adolescent (13-19 years)
Acute	<ul style="list-style-type: none"> • Contusion • Fracture/dislocation • Lyme arthritis • Osteomyelitis • Poor shoe fit • Reactive arthritis • Septic arthritis • Transient synovitis • Vasooclusive crisis of sickle cell disease • Foreign body 	<ul style="list-style-type: none"> • Child Abuse • Hand Foot Mouth • Hemarthrosis • IgA vasculitis (Henoch-Schonlein purpura) • Immunization • Salter 1 fracture • Septic hip • Toddler’s fracture 	<ul style="list-style-type: none"> • Salter I fracture • Myositis 	<ul style="list-style-type: none"> • Sprain or strain • Tendonitis
Chronic	<ul style="list-style-type: none"> • Rheumatic disease 	<ul style="list-style-type: none"> • Blount disease • Cerebral Palsy • Developmental dysplasia of hip • Discitis • Kohler disease • Leg length discrepancy • Vertical talus • Systemic JIA 	<ul style="list-style-type: none"> • Legg-Calve-Perthes Disease • Baker cyst • Kohler disease • Leukemia • Tethered cord • Tarsal coalition • JIA • Dermatomyositis • Acute Rheumatic fever 	<ul style="list-style-type: none"> • Chondromalacia of patella • CRPS • Gonococcal arthritis • Herniated lumbar vertebral disc • Hypermobility syndrome • Osteochondritis dissecans • Overuse syndromes • Scoliosis • Slipped capital femoral epiphysis • Tethered cord • Spondylolisthesis • Tumor • IBD • Systemic lupus erythematosus
Miscellaneous Considerations <i>(not specific to age group)</i>	<ul style="list-style-type: none"> • Serum sickness • Patellar dislocation • Peripheral neuropathy • Meningitis • Epidural abscess of the spine • Complex regional pain syndrome 	<ul style="list-style-type: none"> • Bursitis • Cellulitis • Soft tissue abscess • Pyomyositis • Insect envenomation • Bunion 	<ul style="list-style-type: none"> • Ewing sarcoma • Osteosarcoma • Plantar warts • Ingrown toenail • Myositis ossificans • Appendicitis 	<ul style="list-style-type: none"> • Pelvic inflammatory disease • Psoas / pelvic / perirectal abscess • Iliac adenitis • Testicular torsion • Conversion disorder • Rickets

Supersedes: 6/2019

Approved UC Clinical Practice Council and Medical Director 9/2022

Next review 9/2025